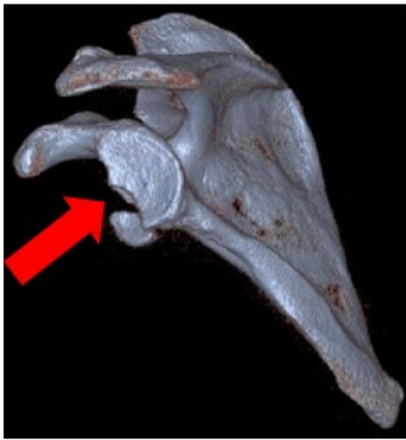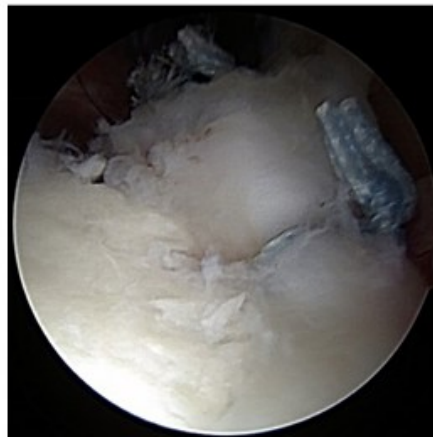


Arthroscopic Glenoid (Bony Bankart) Fracture Repair

- Dr. Chudik developed instruments and techniques to perform arthroscopic repair of the fractured glenoid (socket) following shoulder dislocations.



3-D CT scan of a bony Bankart (shoulder socket) fracture



Arthroscopic image of a bony Bankart fracture and labrum reattached to the glenoid



Dr. Chudik's special bony Bankart repair guide



Patient back to her active lifestyle after bony Bankart repair surgery by Dr. Chudik

STEVEN CHUDIK MD
SHOULDER, KNEE & SPORTS MEDICINE