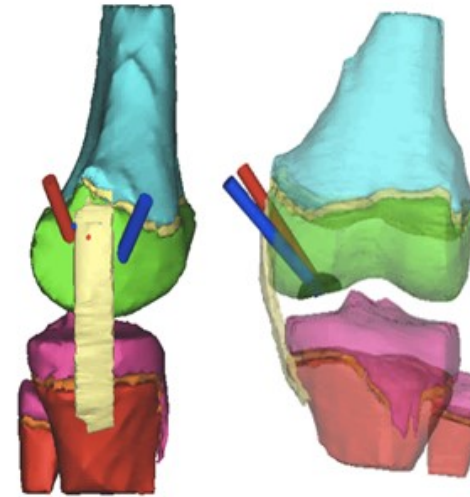


Extra-Articular Repair of Osteochondritis Dissecans (OCD) of the Knee



- Dr. Chudik published anatomic studies and developed techniques and instruments to safely approach OCD lesions from behind to repair them without damaging the overlying cartilage.

The red and blue pegs shown above mark the arthroscopic entry point locations used by Dr. Chudik to repair OCD lesions without damaging knee cartilage depicted in yellow.

Dr. Chudik published paper on knee OCD

STEVEN CHUDIK MD
SHOULDER, KNEE & SPORTS MEDICINE