

# A Novel Arthroscopic Portal for Shoulder Replacement: An Anatomic Evaluation of the Safety and Efficacy

Kimberly A. Bartosiak, BS<sup>1</sup>, Joseph A. Gil, MD<sup>2</sup>, Brittany Kaim Degreef, BS, Steven C. Chudik, MD<sup>3,4</sup>

<sup>1</sup>Loyola University Chicago Stritch School of Medicine, <sup>2</sup>Brown University Alpert Medical School Department of Orthopaedics, <sup>3</sup>Hinsdale Orthopaedics, <sup>4</sup>Orthopaedic Surgery and Sports Medicine Teaching and Research Foundation

## Introduction

Articular cartilage lesions and arthritis involving the glenohumeral joint can be difficult to treat. Conventional methods include arthroscopic debridement, abrasionplasty, microfracture, cartilage restoration procedures, resurfacing and replacement. Restoration, resurfacing, and replacement methods achieve limited access to the glenohumeral joint following subscapularis transection and dislocation. Subscapularis transection delays rehabilitation often resulting in decreased range of motion and permanent weakness. Dr. Steven Chudik developed novel techniques and instruments to access the articular surface without subscapularis transection or dislocation of the glenohumeral joint, allowing for partial and complete

osteochondral transplantation or artificial replacement of the articular surfaces. We propose that utilizing a novel transhumeral portal through the neck of the humerus can decrease surgical morbidity and improve our ability to restore the normal anatomic relationships of the glenohumeral joint. This portal not only is less disruptive to the surrounding structures, but also accounts for patient variability when replacing the humeral surface by referencing from the center of the humeral head and neck. This differs from conventional methods that use the intramedullary canal, which has an inconsistent relationship to the humeral surface.

## Objectives

The purpose of our study is to evaluate the safety and efficacy of creating and using a new, arthroscopic transhumeral portal to expose, prepare and replace damaged glenohumeral joint surfaces without transecting the rotator cuff and dislocating the shoulder. We hypothesize the novel transhumeral portal will safely

avoid the axillary nerve and allow reproducible perpendicular access to both the humeral and glenoid surfaces. We also aim to define surgical landmarks and anatomic relationships (angles) to better facilitate the use of transhumeral surgical instruments.

## Methods

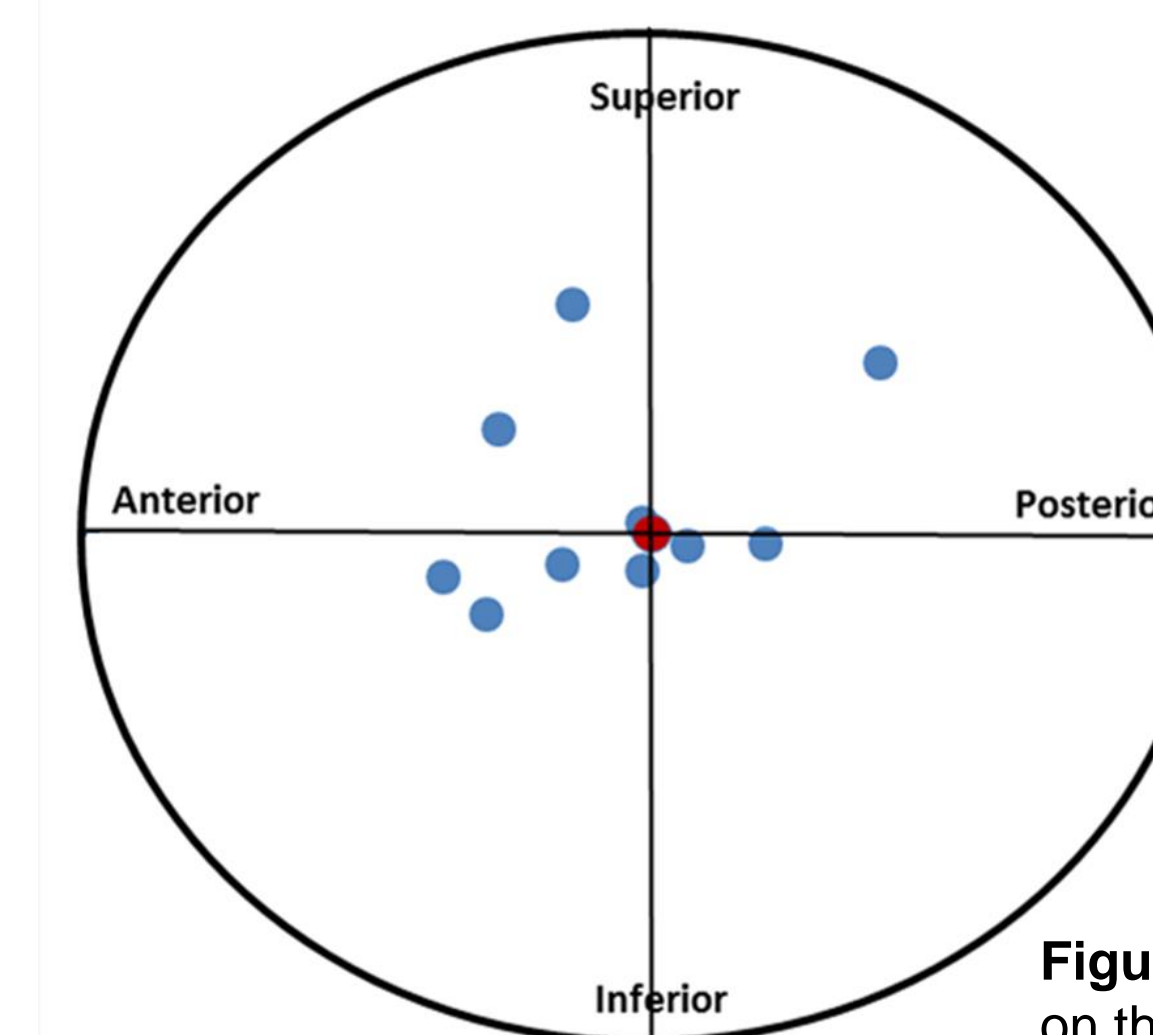
- We created a transhumeral portal in ten fresh-frozen shoulders using arthroscopic visualization and a special transhumeral guide.
- Exposure: Standard anterior and posterior arthroscopic portals were made. A limited anterosuperior exposure of 40 mm was created by sharp vertical incision starting 20 mm inferior to the clavicle and just lateral to the coracoid. The rotator interval was opened in the following manner: laterally to insertion site on humerus and medially, both superior and inferior to the coracoid. The anterior and inferior capsule was released after the subscapularis was retracted anteroinferiorly.
- Transhumeral portal: The target of the transhumeral guide was inserted through the anterosuperior incision and positioned on the center-center of the humeral head under arthroscopic visualization. With the arm in neutral rotation, the cannulated bullet of the transhumeral guide was positioned 8 cm directly inferior to the anterolateral corner of the acromion to form the transhumeral portal. A cannulated bullet was passed through the deltoid to the lateral humeral cortex while the axillary nerve was identified and protected from the anterosuperior incision. The guide pin was passed until contacting the transhumeral guide, then the portal was widened with a small cannulated reamer. The head of the humerus was reamed with a modular reamer which was connected intra-articularly to the shaft directed through the transhumeral portal. After transhumeral drilling a centering hole, the glenoid was reamed with the same intra-articular connection of the reamer.
- After dissection, the supraspinatus and subscapularis were inspected and the following measurements were taken: The distance of the axillary nerve and its branches from the course of the portal, the distance from the portal to the center of the humerus and glenoid, the angle of the portal relative to the longitudinal axis of the humerus, and position of the opening of the bony portal relative to the bicipital groove and the point at which the metaphysis begins to flare from the shaft.
- After all soft-tissue was removed, the portal was redrilled in the opposite direction with the transhumeral guide from the center-center of the humerus, to identify ideal portal entry angle and position lateral to the bicipital groove.

## Results

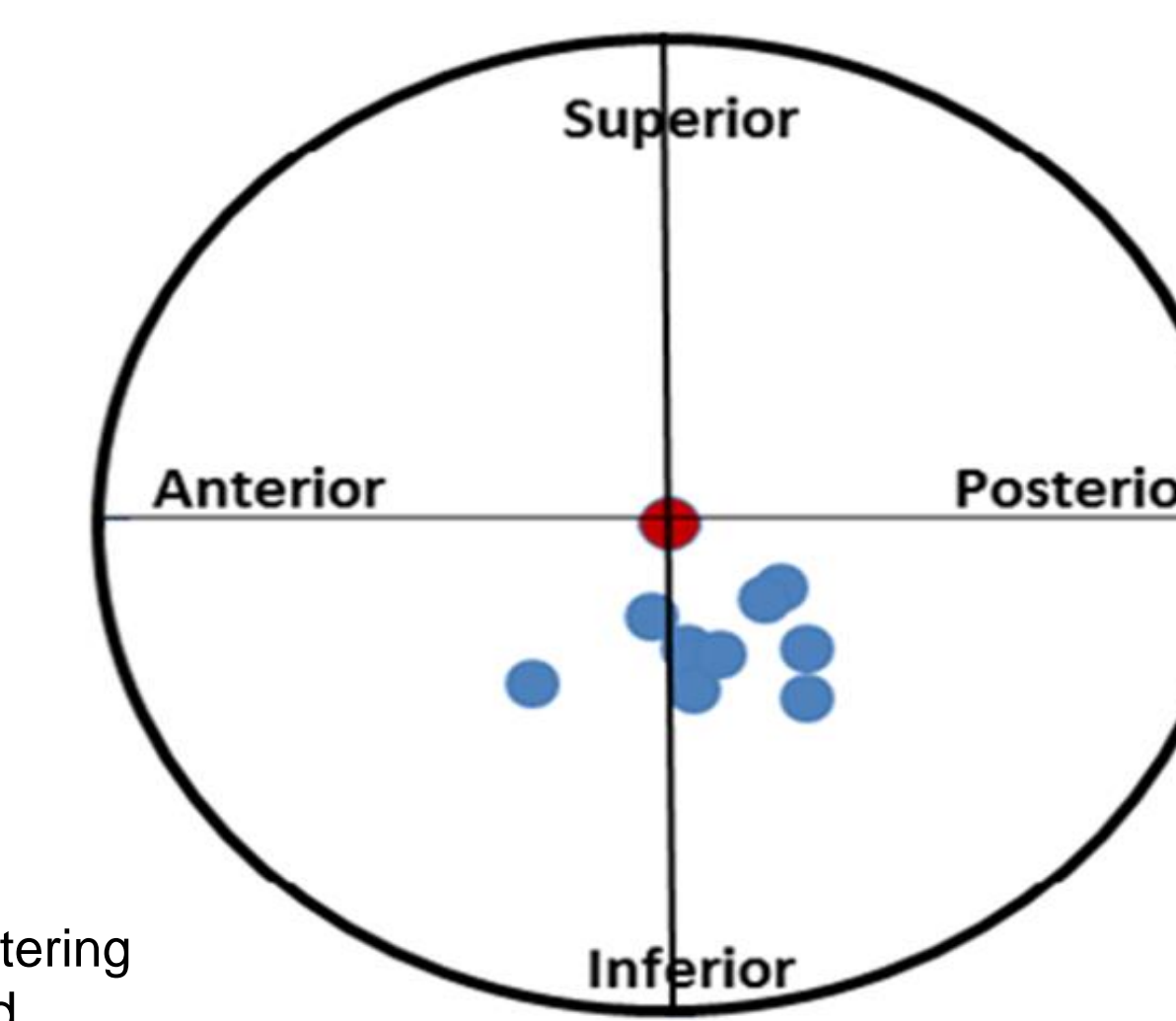
- Dissection revealed the subscapularis and supraspinatus tendons were intact and without damage in all specimens.
- Axillary nerve: The axillary nerve was observed to be intact without injury in all specimens. The mean distance from the soft-tissue path of the transhumeral portal to the main branch of the axillary nerve was 20.7±15.0 mm (Table 1). In all trials, the portal was located antero-superior or inferior to the main branch of the axillary nerve with the posterior division of the nerve branching proximal to the portal.
- Humeral head centering: The mean distance from center of the humerus to the center of the portal was 8.1±5.6 mm. The transhumeral portal exited the humeral articular surface anteroinferiorly (n=4), anterosuperiorly (n=3), posteroinferiorly (n=2), and posterosuperiorly (n=1) relative to the center-center of the humeral surface (Figure 1).
- Glenoid centering: The center of reaming on the glenoid was most often deviated inferior/posterior with mean distance from center of 3.9±1.0 mm. The center of reaming on the glenoid most often deviated posteroinferior (n=8) and anteroinferior (n=2). (Figure 2)
- Humeral entry: The transhumeral portal entered the lateral cortex of the humerus 9.3±7.1 mm lateral to the lateral edge of the biceps groove. The portal entered the humerus on the lateral aspect 7.2 ±2.3 mm superior to the point at which the shaft began to flare into the metaphysis. The transhumeral portal traversed the proximal humerus at an angle of 43.8±6.8 degrees relative to the intramedullary axis of the humerus.
- Ideal humeral entry as determined by re-drilling: The ideal distance from the portal to the lateral edge of the biceps groove was 8.8±2.7 mm with an insertion angle of 46.0±4.3° relative to the humeral intramedullary axis. The portal entered the lateral aspect of the humerus mean 7.5±2.6 mm superior to the point at which the shaft began to flare into the metaphysis, near the inferior margin of the humeral articular cartilage.

**Table 1:  
Relationship of  
portal to Axillary  
Nerve**

Specimen	Distance from axillary nerve (mm)
1	13.3
2	19.0
3	1.3
4	39.3
5	4.7
6	19.0
7	49.3
8	10.7
9	21.7
10	28.7
<b>Average</b>	<b>20.7</b>
<b>Stand Dev</b>	<b>15.0</b>



**Figure 1:** Portal Centering on the Humeral Head



**Figure 2:** Portal Centering on the Glenoid

## Conclusion

This study investigated the safety and efficacy of using a novel transhumeral portal to access and prepare the articular surfaces of the glenohumeral joint. The transhumeral portal demonstrated reliable perpendicular access to the glenohumeral joint surface without surgical dislocation, humeral head resection, nor injury to the proximate important anatomic structures, particularly the axillary nerve and rotator cuff. Although there still remains limitations with regards to

judging the center-center point on the humeral head using arthroscopic guidance alone, this novel transhumeral portal possesses great potential for decreased surgical morbidity, more anatomic replacement of the glenohumeral surfaces, immediate active range-of-motion and strengthening, and better functional outcomes for patients than conventional open approaches.

## References

- Miller SL et al. Loss of subscapularis function after total shoulder replacement: A seldom recognized problem. *J Shoulder Elbow Surg* 2003 Jan-Feb;12(1):29-34.
- Orfaly RM, Rockwood CA, Esenyel CZ, et al. A prospective functional outcome study of shoulder arthroplasty for osteoarthritis with an intact rotator cuff. *J Shoulder Elbow Surg* 2003;12(3):214-21
- Meyer M, Graveleau N, Hardy P, Landreau P. Anatomic Risks of Shoulder Arthroscopy Portals: Anatomic Cadaveric Study of 12 Portals. *Arthroscopy: The Journal of Arthroscopic and Related Surgery* 2007;23(5):529-536.
- Miller SL, Hazrati Y, Klepps S, Chiang A, Flatow EL. 358 Loss of subscapularis function after total shoulder replacement: A seldom recognized problem. *J Shoulder Elbow Surg.* 2003;12(1):29-34.